

## Case Study

### Immediate Implant for a Broken Front Tooth

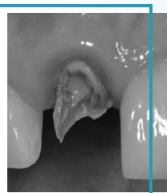Procedure: Single Anterior Tooth Implant with Immediate Loading

Technique Used: **Socket Shield**  
Duration: Same-Day Procedure

#### The Patient's Concern

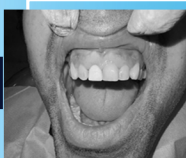A patient visited Restore Dental Gurgaon with a **broken front** tooth and a clear expectation – **an immediate fix**.

The tooth's location in the front made it not only a functional issue but also an aesthetic emergency.



Pre-treatment photo showing broken front tooth

Final smile photo



#### Traditional Treatment Protocols (And Their Drawbacks)

In most dental clinics across Delhi NCR, the standard approach for such cases includes:

- Tooth extraction
- A waiting period of 3 months
- Implant placement with bone graft and membrane (due to post-extraction bone loss)
- Another 3 to 6 months before the crown is placed

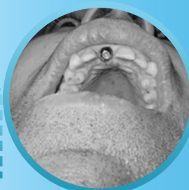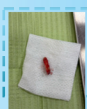**Total treatment time:** 6 to 9 months

This long timeline often adds emotional, aesthetic, and lifestyle stress to the patient.

#### Our Modern Approach One Appointment, One Solution

We opted for an **immediate implant placement** with a temporary crown – all done in a single sitting. What made this possible?

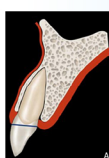**The Socket Shield technique.**



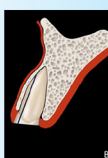
#### What is the Socket Shield Technique?

A minimally invasive and advanced surgical procedure where a **small fragment of the patient's tooth root is preserved** during extraction. This preserved "shield" protects:

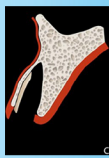
- The natural **bone structure**
- The surrounding **gum contour**
- The overall **smile aesthetics**



Horizontal section of the tooth



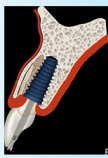
Mesiodistal section with the removal of the palatal half



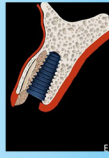Preparation of the buccal shield



Creation of a chamfer bevel



Implant placement

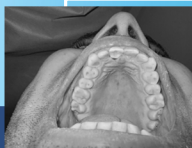

Temporary provisional restoration [Courtesy of Gluckman et al. 2018]]

#### Step-by-Step Summary of the Procedure

1. Careful extraction of the broken tooth
2. Partial root fragment retained using Socket Shield
3. Immediate implant placed into the socket
4. A temporary crown was fixed, restoring aesthetics and bite

Implant placement photo



#### Results

The patient walked out the same day with:

- A fully restored smile
- No bone loss
- No waiting period
- No multiple surgeries

Final smile photo



Discuss your case with **Dr. Divyesh Mehta & Dr. Ankita Wali** and get a **Second Opinion**

+91-9711518504

#### Useful Articles

Do I need a crown after undergoing a root canal treatment?

Invisalign vs. Braces – Which One Should You Choose?